

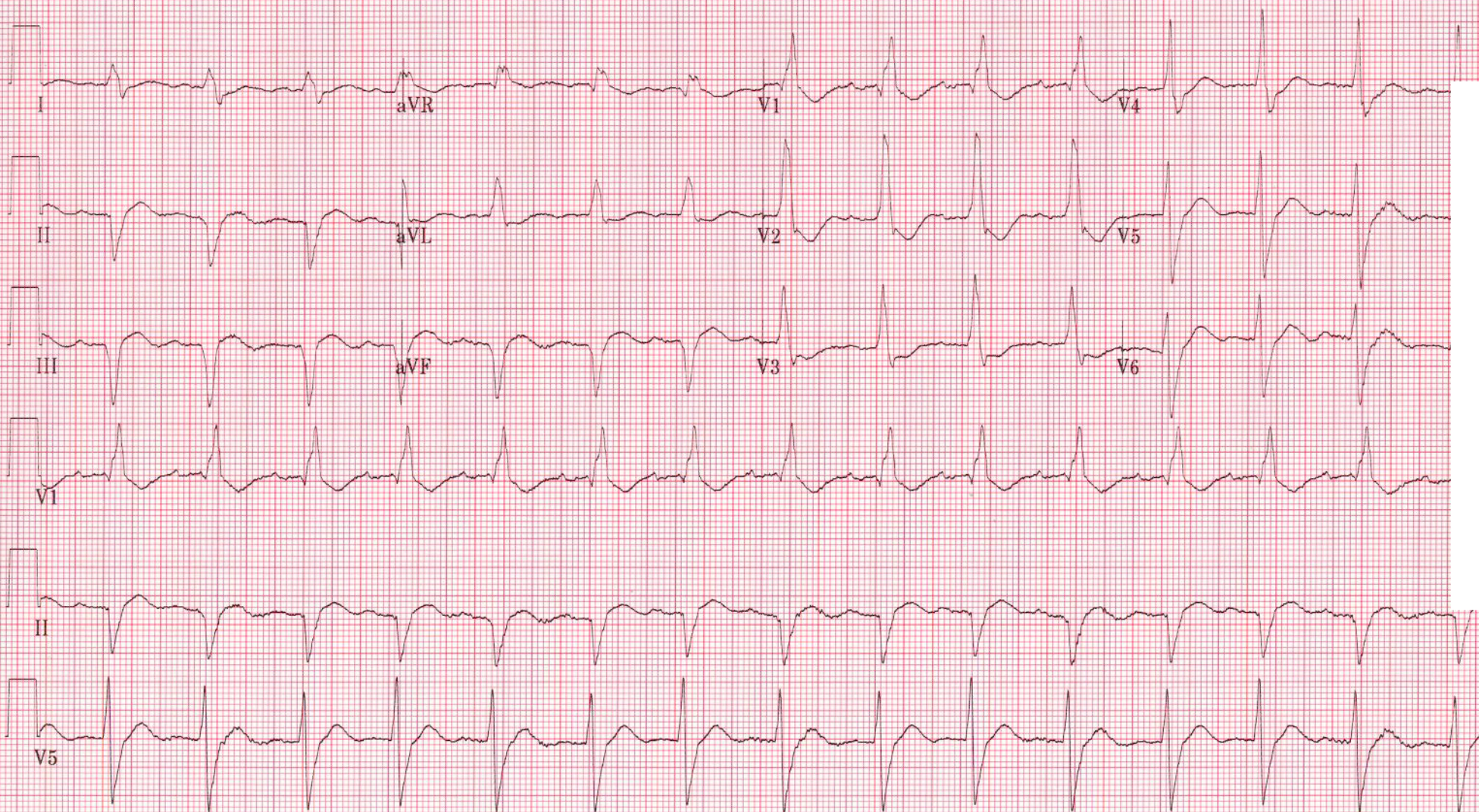
21-Mar

10:09:21

89years
Male Black

Vent. rate 90 bpm
PR interval 214 ms
QRS duration 142 ms
QT/QTc 394/481 ms
P-R-T axes 44 -82 64

Sinus rhythm with 1st degree AV block
Left axis deviation
Right bundle branch block
Inferior infarct, age undetermined
Abnormal ECG



150 Hz 25.0 mm/s 10.0 mm/mV

4 by 2.5s + 3 rhythm lds

PRINTED IN U.S.A.